

## EFFECTS OF CRYOLIPOLYSIS WITH PLATES IN LOCALIZED ADIPOSITY WITH THE CRIOPPLACE™ CONCEPT

Patrícia Froes Meyer<sup>1</sup>; Rodrigo Marcel Valentim da Silva<sup>1\*</sup>; Felipe Rodrigues de Souza<sup>2</sup>, Stephany Luanna Queiroga Farias<sup>2</sup>; Liliane Santos de Vasconcelos<sup>1</sup>; Eneida de Moraes Carreiro<sup>2</sup>; Fábio dos Santos Borges<sup>3</sup>.

<sup>1</sup> Federal University of Rio Grande do Norte (UFRN), <sup>2</sup> Potiguar University, Natal/RN,

<sup>3</sup> Estácio de Sá University, Rio de Janeiro/RJ.

\*For correspondence: rodrigomarcervalentim@gmail.com

### Abstract

**BACKGROUND:** Plate cryolipolysis is a method of applying cooling without a vacuum system, which can be used in regions with less possibility of skin suction or fibrosis. **OBJECTIVE:** This study aims to investigate the effects of cryolipolysis with the use of plate-shaped applicators (CrioPlace™) for localized fat treatment. **METHODS:** The sample consisted of men aged 20 to 45 with complaints of localized adiposity in the abdominal region and flanks. Two plates were positioned in the flank and abdomen regions, respectively. They received two 60-min applications in the temperature of -2°C. The anthropometric, thermographic and ultrasound assessments were performed, and a satisfaction questionnaire was applied after treatment. The reevaluations occurred 30 and 60 days after the first intervention. **RESULT:** A reduction in adiposity was observed in flank region plicometry ( $p < 0.05$ ) and abdominal and flank ultrasound ( $p < 0.05$ ). About 66.7% of the volunteers reported less water retention, about 41.7% reported that their clothes were looser, and 100% reported overall satisfaction. Fifty percent rated the treatment as excellent and 58.3% felt improvement in overall aesthetics. **CONCLUSION:** The CrioPlace™ method was effective in reducing localized adiposity, with clinical satisfaction of measurement reduction, both in plicometry and ultrasound analyses, with highlights to the flank region results.

**Keywords:** Adipose tissue, cryotherapy. ultrasonography.

### INTRODUCTION

The cryolipolysis is a method that uses cooling to eliminate localized adiposity, effects that are reported in the scientific literature (1, 2). After cooling, inflammatory response occurs in adipose tissue, resulting in adipocyte apoptosis and reduced measurements (3). Lipolysis occurs due to adipocyte crystallization related to inflammatory responses. The inflammation triggers a progressive and continuous reaction in adipose cells with the destruction of cell membranes by inducing a cellular apoptosis mechanism (3, 4). Another mechanism is the alteration of adipose cell metabolic activity, inducing hormonal and biochemical adaptations that favor the metabolism of fat reserves (5, 6).

In cryolipolysis equipment, an average temperature reduction to as low as -15°C is observed. In addition to cooling, the technique application is characterized by a suction

mechanism performed by the applicator, which pulls the subcutaneous tissue into the applicator via a negative pressure, intensifying localized cooling. Despite the suction mechanism, no significant damage to the dermis and epidermis is observed, intensifying the response only in subcutaneous tissue (7).

The use of equipment without the suction system with the application of cryolipolysis in a plate system is investigated. This modality of cryolipolysis does not use suction and only cooling is applied. Therefore it could minimize complications that may result from suction and could be applied in areas of difficult coupling. The technology of flat applicators that promotes cooling, however, allows the treatment of specific areas in the body contour. But studies with important results in the application in the abdominal region have not been published. It is suggested that the effects of the application of cryolipolysis with the use of specific applicator

in the treatment of localized abdominal fat in men is investigated (8, 9, 10).

The use of plate cryolipolysis has been carried out in clinical practice in the treatment of "non-reachable" areas such as breeches, the upper abdomen, and other areas with fibrotic tissue concentration. A disadvantage is the need for a longer application session when compared to traditional cup applicators (8, 9). In a sample of 40 patients, the application time was 1 h 20 m with a  $-5^{\circ}\text{C}$ -temperature, in which there was a reduction in adiposity in the breeches region, verified by ultrasound and photographs (9).

Based on these fundamentals, a new model of plate cryolipolysis equipment was developed and the study aimed to investigate the effects of cryolipolysis using a specific plate applicator, called CrioPlace™ in the treatment of localized adiposity.

## MATERIALS AND METHODS

The study is an experimental, prospective, randomized clinical trial in compliance with the Consolidated Standards of Reporting Trials, (CONSORT transparent reporting of trials, 2010), performed at the dermatofunctional physiotherapy outpatient clinic, an integrated clinics of the University - UnP, Natal/RN.

The sample population consisted of 30 men aged 25-45 with a mean age of  $30.9 \pm 5.8$  years, who had localized adiposity in the abdominal, infra-umbilical, and flank regions. Volunteers meet the following inclusion criteria: body mass index (BMI) between 18.5 and 29.99 (normal to overweight mean value  $26.99 \pm 3.14$ ); with adiposity located in the infra-umbilical region and flanks greater than 1 cm and less than 4cm-thick, not taking anti-inflammatory drugs at least for 1 week before the study. Volunteers who did not perform the proposed evaluations, missed consecutive treatment sessions, increased excess weight during the study, or had severe dermal reaction or decreased sensitivity were excluded.

This study was submitted to the Research Ethics Committee (CEP) and approved by the Potiguar-UnP University Committee (Approval number: 3.308.208). Participants were advised on the procedures they would undergo and signed the informed consent form, in accordance with National Health Council Resolution 466/12 and in line with the Declaration of Helsinki.

### Instruments

The Criodermis™ cryolipolysis equipment manufactured by Medical San (Lajeado, RS, Brazil) was used. CrioPlace™ vacuum-free applicators were used, measuring respectively

(width×length):  $10 \times 15$  cm, and  $7.5 \times 10$ cm, antifreeze membrane: weighing 400g and measuring  $40 \times 30$ m (All Care, RMC), fat analyzer: MSLPU35 Linear Wireless Probe Ultrasound Imaging Scanner (10Mhz) (Guangzhou Medsinglong Medical Equipment Co), thermographic camera (C2, Flir), and camera (SX530 HS, Canon).

### Experimental Protocol

The volunteers were evaluated three times during the study: before treatment, 30 and 60 days after treatment. Waist and hip perimeters, photographs, plicometry, weight were taken, and thermographic and ultrasound analyses were performed during all evaluations.

The perimetry was measured with the volunteers in an orthostatic position, with the tape measure positioned at two levels in the abdominal region: 4 cm above the umbilical scar, and 4 cm below the umbilical scar. The plicometry was performed with the volunteers in an orthostatic position, being the manual fold and the tweezing performed on the left and right lateral regions, 4 cm below the umbilical scar. Photos were taken while standing, all wearing swimwear or underwear. Frontal, left and right shots were taken in neutral colored background for image standardization. Body weight was measured with a bathroom scale, wearing swimwear or underwear.

Immediately after the removal of the applicators and antifreeze membrane, infrared images were taken with the thermographic camera, in order to evaluate the thermal profile of the treated areas, and for association of the performance of the plate cryolipolysis equipment with the collected results.

Ultrasonography was performed in the infra-umbilical region 4 cm below the umbilical scar and in the flank region, in the middle portion between the iliac crest and the last rib. A mobile  $10 \times 10$  cm area delimiting outline was positioned in the center of the infra-umbilical region and below the waist on both sides. The measurement region was outlined with the volunteer standing and ultrasound examination was performed in the supine position, with no pressure caused by the applicator against skin.

All 30 volunteers received 2 sessions of cryolipolysis treatment in the infra-umbilical and flank regions, with a period of 30 days between sessions. The infra umbilical region was treated with 2 applicators measuring  $10 \times 15$  cm; and the flank region with two applicators measuring  $7.5 \times 10$ cm applicators; In the abdominal region, applicators were positioned side by side, covering the target region.

Two applications were 60 minutes at 2°C as the set temperature parameter, with an interval of 30 days between sessions. One week after the second treatment, the volunteers were re-evaluated by the same methodology as used prior to the treatment. In addition to the local physical re-evaluation, the volunteers are asked to answer a questionnaire for reporting the occurrence of possible adverse and/or deleterious effects that could have occurred during and after treatment, and about their satisfaction with the results. The Global Aesthetic Improvement Scale (GAIS), by Narins<sup>11</sup>, and the satisfaction questionnaire adapted from Segot-Chicq et al (2007) <sup>12</sup> were applied (19). Based on these questionnaires, a comparative skin aspect questionnaire was developed for use before and after the CrioPlace™ treatments, here named the Adversity Questionnaire.

In addition to evaluation and reassessment, the volunteers were followed-up for four months after treatments, and interviewed to verify the occurrence of any adverse effect that may have resulted from the procedure. Ultrasound image, anthropometric measurement and thermographic image were analyzed to calculate the reduction of the fat layer.

To better define the parameters used in the research, a pilot study was performed to verify the tissue cooling promoted by the equipment. In this study, a cryolipolysis prototype equipment was used with the Medical San's CrioPlace™ application method. In this test, the temperature was checked in 5-minute intervals for a period of 60 minutes, with the temperature observation carried out with the assistance of an infrared thermometer and a thermographic chamber. The pilot study identified an average temperature of -2°C in the cooling plate, and of 0°C in the patient's skin during the full application period.

## Data analysis

Descriptive and inferential data statistics were performed using the SPSS 22.0 software. Data normality was observed using the Kolmogorov-Smirnov test. For comparison of measurements of all evaluations (pre-treatment, 30, and 60 days from treatment), the Bonferroni post hoc repeated measures and the ANOVA test were applied. A significance level of 95% ( $p < 0.05$ ) was adopted.

## RESULTS

According to the study protocol, two months after the intervention, six volunteers withdrew from the research, and 24 volunteers remained for the entire duration of the study.

**Table 1** shows the results of comparison among different observation time points for the anthropometric and ultrasound variables. There was a reduction in the plicometry measures in the flank region on both sides after 60 days and on ultrasound in the flank and abdominal region.

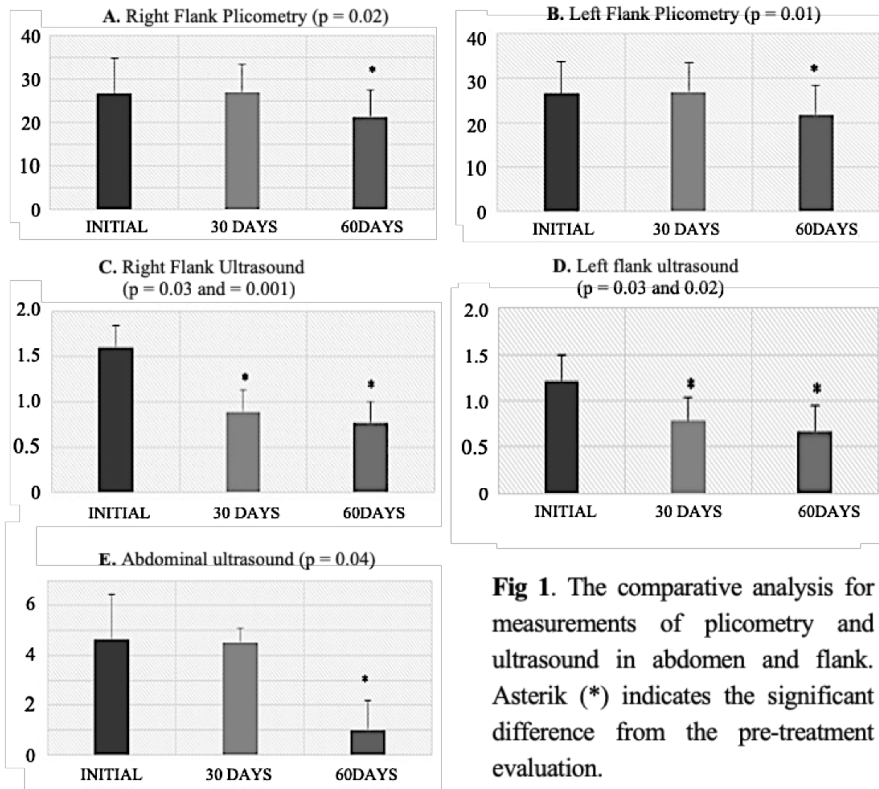
**Fig 1** presents the measurements of flank plicometry on both sides, as well as flank and abdominal ultrasound. There were significant differences in the variables of plicometry and ultrasonography. The analysis of right and left plicometry shows a reduction between the initial evaluation and evaluation after 60 days ( $p = 0.02$  and  $p = 0.01$ ). In abdominal ultrasound results, a reduction was verified after 60 days ( $p = 0.04$ ); ultrasound results for the right flank region at 30 days ( $p = 0.03$ ) and 60 days (0.001); and left flank at 30 days ( $p = 0.03$ ) and 60 days ( $p = 0.02$ ).

**Fig 2** shows the ultrasound images of the abdomen, right and left flanks, for visualization of changes at baseline, 30 and 60 days. **Fig 3** presents clinical photographs of 2 patients before and after the interventions proposed in the study.

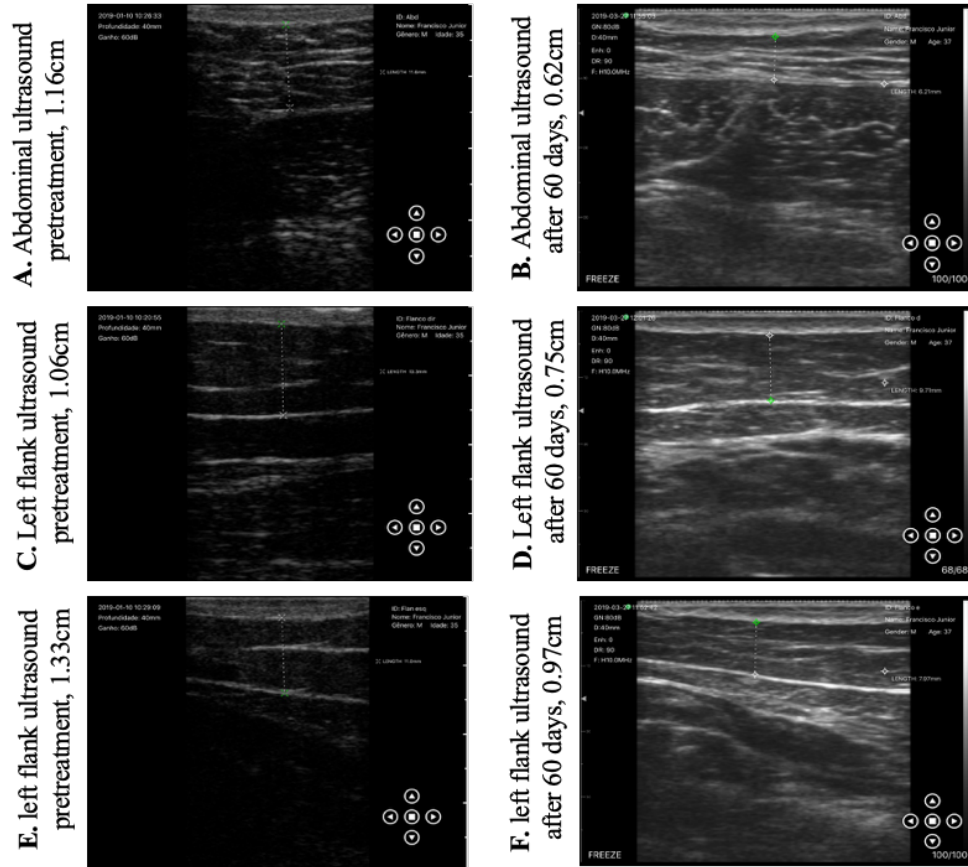
**Table 1.** Comparison of anthropometric variables and ultrasonography.

Parameters	Pre-treatment	30 days	60 days	p value
Weight (Kg)	77.2±16.0	78.98±16	78.5±17	0.92
BMI (Kg/m <sup>2</sup> )	26.99±3.1	25.42±8.1	26.7±6.2	0.87
Infraumbilical Plicometry (cm)	95.34±6.8	93.7±7.37	96.10±8.4	0.89
Right abdominal plicometry (cm)	31.44±5.4	31.98±5.7	29.72±6.2	0.84
Left abdominal plicometry (cm)	26.63±8.1	26.83±6.56	25.22±6.2	0.76
Left flank plicometry (cm)	26.63±8.1	26.83±6.5	21.22±6.2	0.02*
Right flank plicometry (cm)	26.53±7.2	26.82±6.5	21.65±6.6	0.01*
Waist perimeter (cm)	92±7.1	90.7±6.5	91.08±6.3	0.89
Hip perimeter (cm)	102.38±5	102.54±6.5	102.3±6.2	0.96
Ultrasound right flank (cm)	1.21±0.2	0.78±0.2	0.66±0.2	0.001*
Ultrasound left flank (cm)	1.00±0.24	0.89±0.24	0.77±0.2	0.03*
Ultrasound anterior abdominal (cm)	4.63±1.8	1.51±0.59	1±1.2	0.04*

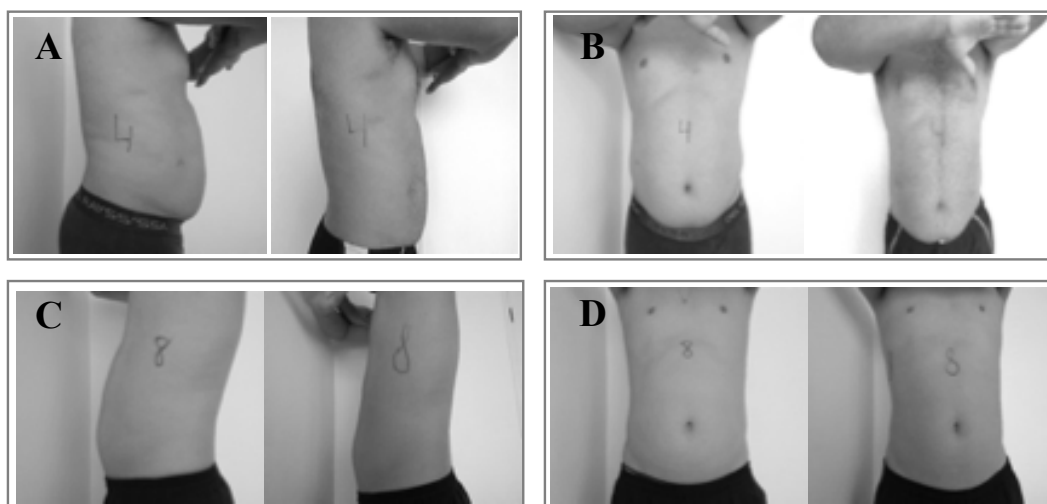
\* There was a statistically significant difference.



**Fig 1.** The comparative analysis for measurements of plicometry and ultrasound in abdomen and flank. Asterik (\*) indicates the significant difference from the pre-treatment evaluation.



**Fig 2.** The ultrasound images of the abdomen, right and left flanks for visualization of changes at baseline, 30 and 60 days.



**Fig 3.** (A, B) Photographic analysis of patient No. 4 before and after 30 days from the last intervention. (C, D) Photographic analysis of patient No. 8 before and after 30 days from the last intervention.

**Table 2.** Adverse effects and clinical satisfaction regarding the aesthetic interventions.

Questions and Answers	AF	RF
Fluid retention decrease		
Yes	16	66.7
No	7	29.2
Did not answer	1	4.2
Mild shocks during applications		
No	22	91.7
Yes	3	8.3
Noticed loose clothing		
No	2	8.3
Yes	10	41.7
In the first week	6	25.0
From 4 weeks	6	25.0
Satisfaction with the results		
I consider skin much firmer	24	100.0
Treatment evaluation		
Excellent Treatment	11	45.8
Very Good Treatment	6	25.0
Good Treatment	6	25.0
Did not answer	1	4.2
Scale of overall aesthetic improvement		
Unchanged	6	25.0
Better	14	58.3
Much Better	3	16.7
Did not answer	1	4.2

**Table 2** presents the results of the GAIS questionnaires and satisfaction questionnaire. Questionnaires were applied after the final evaluation. About 66.7% of volunteers reported fluid retention decrease, 7% of volunteers felt mild shocks during the sessions, about 41.7% reported loose clothing, and 100% reported

satisfaction with end results. It was observed that 45% of volunteers rated the treatment as “excellent” and 20.8% reported them to be “very good”, while and 70.8% reported an overall aesthetic improvement.

## DISCUSSION

There was no body weight variation at different study time points for any comparison in anthropometric measurements, demonstrating the maintenance of localized adiposity weight distribution. Measurement reduction did not occur significantly in waist and hip perimeters. In the flank plicometry, a similar behavior was observed on the right and left sides. For both sides, the reduction of the skinfold measurement at 60 days is observed with comparison to the pretreatment timepoint. Ultrasound evaluation showed that CrioPlace™ reduces adipose tissue after 60 days in the abdominal region, and in the flank region, the reduction occurred bilaterally, both after 30 and 60 days.

The reduction in fat thickness of the treated area without the concomitant weight reduction characterizes an indicative response to the treatment applied to localized adiposity. The observation is similar to the findings reported in literature. In studies concerning adiposity analysis, there was no weight reduction, but there was a decrease of localized adipose tissue, as seen in plicometry, perimetry, and ultrasound measurements (3, 5, 14). Such results may be explained by the adipose tissue cooling effect, which induces the mechanism of cellular apoptosis. This induction promotes modification of the adipose tissue organization through cryolipolysis through an intense decrease in

local temperature, obtained through a cooling plate coupled in the region selected for treatment (6, 8). In conventional cryolipolysis, adiposity is retained within the applicator due to the negative pressure caused by the intense suction that is applied to the area for an average time of 60 minutes. The cup-shaped applicator uses a moderate suction mechanism to suck the skin and fat layer into the coupling system, forming a skinfold that is held and cooled down between the two plates. One study has shown that under temperature conditions of 1°C, adipocyte cells have a reduced chance of survival (13, 14, 15). However, the applicator of the CrioPlace™ method does not have a suction system, and the cooling mechanism is promoted by cooling plates that work similarly to the conventional cryolipolysis devices. Few studies presented the results of a suction-free cooling system. They have shown results of reduced adiposity and increased satisfaction with clinical intervention with little adverse effects (6, 8, 16, 17, 18)

Measurements were reduced in the abdomen and flanks, and the result was greater in flanks (plicometry and ultrasonography). In the ultrasound, plicometry and photographic analyses, the most prominent results were observed after 60 days. Both responses found in this study corroborate with literature findings, as seen in a review by Kennedy et al. (19), who analyzed more than 27 studies and about 3000 patients who underwent cryolipolysis treatment. Other authors (10, 17) also observed a greater effectiveness in the flank region and a better result 60 days from of intervention. Therefore, the CrioPlace™ method presented a response similar to that demonstrated with the suction cryolipolysis. Friedmann et al. (18), with the vacuum-free applicators in the infraumbilical region, verified the reduction of adiposity using the ultrasound and also with the application of questionnaires. Their results were more significant after two applications, which also corroborates with the present study.

The literature on cryolipolysis suggests two months of treatment, with the greatest results on the flanks and abdomen (19, 20). The reduction in adiposity in the flank region coincides with the response observed in other studies, which found that this region was the most sensitive to the effects of different cryolipolysis equipment (19, 20, 21, 22). Reports of looser clothing and reduced fluid retention coincide with studies carried out by Meyer (7), who used cryolipolysis with the conventional applicators on flanks, obtaining similar responses. In addition, studies carried out by the same author and that used other cooling mechanisms to reduce adiposity

have also yielded results with satisfactory patient reports, such as the use of cryofrequency 23 and contrast cryolipolysis (21).

Regarding satisfaction with the treatment outcome, similar answers were found with conventional cryolipolysis works (3, 6, 8, 17, 22). The CrioPlace™ method, even with less intense cooling than the applied in other studies and with shorter application sessions, showed localized adiposity reduction. The average plaque temperature was 2°C, with the patient's skin temperature at 0°C. In other published experiments using plate cryolipolysis, more intense cooling temperatures ranged from -5°C to -13°C (7, 8, 9, 10, 18, 22).

The limitations of this study were the absence of a control group or placebo, which could favor a better result interpretation, and also the absence of histological and immunohistochemical analyses to further clarify the effect of this treatment on adipose tissue.

The CrioPlace™ method was effective in reducing localized adiposity, with high clinical satisfaction due to body measurement reduction, both acknowledged through plicometry and ultrasound analyses, with greater effectiveness in the flank region. It concludes that the CrioPlace™ method can be effectively and safely used to reduce localized adiposity in the abdomen and flanks.

**Acknowledgements:** We thank all volunteers in this study.

## REFERENCES

1. Alizadeh Z, Halabchi F, Mazaheri R, Abolhasani M, Tabesh M (2016) *Int J Endocrinol Metab* 14(4): e36727.
2. Bernstein EF, Bloom JD, Basilavecchio LD, Plugis JM, Suh DH, Park JH, Jung HK, Lee SJ, Kim HJ, Ryu HJ (2018) *J Cosmet Laser Ther* 20(1):24-27.
3. Bernstein EF (2016) *J Cosmet Dermatol* 15(4):561-564.
4. Bernstein EF, Bloom JD, Basilavecchio LD, Plugis JM (2014) *Lasers Surg Med* (2014) 46(10):731-5.
5. Bertolini SMG.; Coelho KC; Fries LMV; Sorti GS; Zorzi YR (2015) *Rev Científica JOPEF* 19(1).
6. Boey E, Wasilenchuk JL (2015) *Lasers Surg Med* 46(1):20-6.
7. Braz AEM, Marcelino BTL, Lopes FA, Pires LM, Moreira LA. Faria MRD, Machado MA, Rodrigues RVA, Lima P (2019) *BosiFisioterapia Brasil* 3(18): 339-344.

8. Derrick CD, Shridharani SM, Broyles JM (2015) *Aesthet Surg J*. 35(7):830-6.
9. Friedmann DP (2019) *Dermatol Surg* 2019 Jan 21.
10. Kennedy J, Verne S, Griffith R, Falto-Aizpurua L, Nouri K (2015) *J Eur Acad Dermatol Venereo* 29(9):1679-88.
11. Kilmer, SL (2017) *Lasers Surg Med* 49(1):63-68.
12. Lipner SR (2018) *J Cosmet Dermatol* 17(2):145-151.
13. Meyer PF, Consulin MCD, Rodrigues T, Pereira AM, Lopes PCM, da Silva RMV, de Vasconcellos LS (2018) *J Cosmet Dermatol* 17(6):1059-1062.
14. Meyer PF, Davi Costa E Silva J, Santos de Vasconcellos L, de Moraes Carreiro E, Valentim da Silva RM (2018) *Clin Cosmet Investig Dermatol* 11:499-503.
15. Meyer PF, Furtado ACG, Moraes SFT, de Araujo Neto LG, Valentim da Silva RM, Medeiros ML, Maciel de Queiroz CA (2017). *CryoLetters* 38(5):379-386.
16. Narins RS, Brandt F, Leyden J, Lorenc ZP, Rubin M, Smith S (2003) *Dermatol Surg* 29(6):588-95.
17. Putra IB, Jusuf NK, Dewi NK (2019) *Open Access Maced J Med Sci* 7(9):1548-1554.
18. Savacini MB, Bueno DT, Molina ACS, Lopes ACA, Silva CN, Moreira RG, Almeida S, Guidi RM, Sant'Ana E, Liebano RE (2018) *Dermatol Res Pract* 2018:5276528.
19. Segot-Chicq E, Compan-Zaouati D, Wolkenstein P, Consoli S, Rodary C, Delvigne V, Guillou V, Poli F (2007) *J Eur Acad Dermatol Venereol* 21(9):1181-6.
20. Stevens WG, Bachelor EP (2015) *Aesthet Surg J* 35(1):66-71.
21. StevensWG (2016) *Plast Reconstr Surg* 138(1):153e-5e.
22. Valentim da Silva RM, Silva MWT, Medeiros SF, Guerra SSB, Regina da Silva Nobre, Meyer PF (2018) *MTP & Rehab J* 16: 551